

Endovascular Management of Paragangliomas

MOHAMED SHADAD MD., PHD. AND AHMED ELSHARKAWY MD., PHD.

Department of Neurosurgery, Faculty of medicine, Tanta University

Abstract

Background: Paragangliomas of head and neck are highly vascular tumors, which coupled their surgical excision with high morbidity. Preoperative transarterial super selective embolization markedly improved safety of their surgical excision.

Methods: This is a retrospective non-randomized clinical and angiographic study of all ten patients with paragangliomas who undergone preoperative embolization in Department of Neurosurgery - Tanta university between 2010 and 2016.

Results: The ten patients had 11 paragangliomas. 80% of patients were females. The average age of patients was 47 years. All patients had pain and pulsatile tinnitus at diagnosis. Paragangliomas subtypes comprised 8 temporal, 2 carotid body and one vagale tumors. The average reduction of paraganglioma vascularity after embolization was 80%.

Conclusions: Preoperative transarterial embolization of head and neck paragangliomas is a very safe and effective adjuvant to surgical excision.

Introduction

Paragangliomas, also known as glomus tumors, are highly vascular neoplasms, which arise from chemoreceptor cells of the paraganglia or glomus bodies. Paragangliomas rare tumors with incidence ranging from 1 in 30000 to 1 in 100000. In the head and neck, common sites involve carotid body, temporal bone (glomus tympanicum and glomus jugulare) and vagus nerve (glomus vagale) descending order of frequency . Usual age is fifth decade (younger in familial cases) with female predominance of 3:1 except for carotid body tumors. Multiplicity is common especially in familial cases (10% in non familial versus 30% in familial cases) . [1-5].

Paragangliomas generally cause clinical symptoms by local bone invasion and infiltration of the bordering structures depending on tumor location. Carotid body tumors usually present as painless slowly growing neck mass. Temporal paragangliomas typically cause hearing loss, pulsatile tinnitus and cranial nerve palsy. Hormone secretion, lymph node involvement or metastases are unusual presentations for head and neck paragangliomas. The Fish classification evaluates tumors on a scale of A through D, with A representing localized tympanic tumor, B mastoid extension, C erosion of the carotid canal (with

subtypes), and D indicating intracranial extension. [4,6,7].

Radiological examinations are essential for accurate evaluation of paragangliomas and treatment planning. CT shows the extent of bone erosion. MRI shows the extent of tumor growth, vascular encasement and invasion of intracranial structures. MRI shows high velocity flow voids within the tumor giving the characteristic salt and pepper appearance. Conventional angiography typically shows enlarged feeding arteries, dense tumor vascular blush and early venous drainage. Paragangliomas are classically multi-compartmental tumors. Each compartment has its own arterial feeder and draining vein requiring multiple super-selective catheterizations to completely study or embolize the tumor.[8, 9]

Available treatment options for head and neck paragangliomas comprise radiation therapy, surgical excision or combination of both. Surgical excision used to be associated with extreme morbidity due to excessive blood loss and cranial nerve palsy. Transarterial embolization is a proven treatment modality for preoperative devascularization of these lesions to improve the situations under which surgery is executed. Nowadays, complete surgical resection of paragangliomas, after preoperative embolization of external carotid feeders with PVA particles, has been the primary management plan leaving radiation therapy mostly for unresectable or residual tumors.[1, 2, 10-20]

Aim of the work

In this report, we evaluate safety and efficacy of preoperative endovascular embolization of head and neck paraganglioma and present our experience with this procedure at department of neurosurgery, Tanta University, Egypt.

Patients and Methods

We included all patients with head and neck paraganglioma referred to us for preoperative embolization between 2010 and 2016. All patients subjected to detailed history taking, complete clinical and neurological examination, audiometric evaluation, full laboratory investigations including 24-hour urinary catecholamine, and finally full radiological evaluation including CT and MRI scans.

Under general anesthesia standard trans-femoral approach were applied in all cases. Using 5 F multipurpose diagnostic catheter diagnostic angiography done in all cases to check tumor feeders and to define dangerous anastomosis with internal carotid and vertebral arteries. Evaluation of venous drainage and venous sinuses if invaded. Balloon occlusion test to evaluate collateral supply if ICA encased and there is possibility to sacrifice ICA.

Replacement with 6 F guiding catheter done in all cases. Combination of different microcatheters and microwires used according to diameter of feeders, target point of injection (selective or super-selective), size of PVA particles intended for injection (150-1000 micron). Starting from 150 micron particles injected in pulsed manner targeting tumor bed until disappearance of the tumor blush while repeated control DSA repeated to check opening of dangerous anastomosis. Control DSA at the end to evaluate embolization done. Surgical excision preferred in first 48 hours post embolization.

Results

A total of 10 patients with 11 paragangliomas in the head and neck region underwent preoperative superselective arterial embolization of their lesion. Eight patients were females and 2 patients were males. The average age at presentation was 47 years old (range 31-57 years). Pain, pulsatile tinnitus and hearing loss were the most common clinical symptoms present at time of diagnosis in our series. Other clinical symptoms are listed in table (1). The average sizes of tumors at presentation are listed in table (2). Paragangliomas subtypes included eight temporal (tympanicum and jugulare), two carotid body and one vagale tumors.

The Ascending pharyngeal artery was the main arterial feeder for paragangliomas in all our cases. The inferior tympanic and neuromeningeal branches of the Ascending pharyngeal artery were the main feeders in temporal paragangliomas. Some of these temporal paraganglioma had supplementary feeders from occipital, the middle meningeal arteries,

extradural branches of internal carotid artery and intradural branches with intracranial extension from internal carotid artery or vertebral-basilar system. The musculospinal branch of the Ascending pharyngeal artery was the main feeder of all carotid body tumors and vagal paragangliomas. (Table 3)

total and subtotal (90-100%) disappearance of tumor blush achieved in 8 patients while incomplete (60-89%) disappearance of tumor blush achieved in two patients. Necrosis evaluated by absent enhancement or decrease of contrast uptake in post embolization contrast CT and MRI.

No permanent morbidity or mortality in our series. All patients had transient mild post embolization pain that resolve with steroids and analgesics. Femoral artery dissection without sequel occurred in 1 patient with sheath insertion and sealed by blood flow and prophylactic anticoagulation given with normal Duplex study in second postoperative day. Surgical reports, of our series, showed dramatic effect of preoperative embolization on limiting the amount of intraoperative blood loss and decreasing neurologic morbidity during surgical excision of paraganglioma. The average intraoperative blood loss was 900 ml for glomus jugular, 500 ml for carotid body and 600 ml for glomus vagale.

Table 1: Presentations

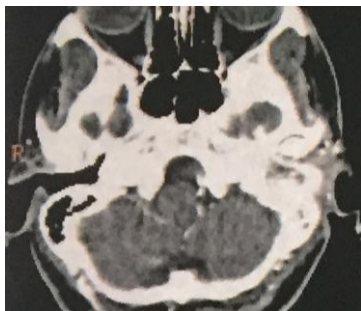
Symptoms	No.	%
<i>Pain</i>	9	90%
<i>Pulsatile tinnitus</i>	8	80%
<i>Hearing loss</i>	6	60%
<i>Vertigo</i>	4	40%
<i>Pulsatile mass</i>	3	30%
<i>Cranial nerve deficit</i>	2	20%

Table 2. Tumor size

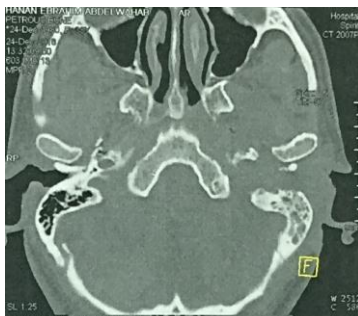Location	Range (in mm)	Median (in mm)
<i>Temporal</i>	15 - 60	40
<i>Carotid body</i>	50 - 90	70
<i>Vagale</i>	30	30

Table 3: Arterial feeders

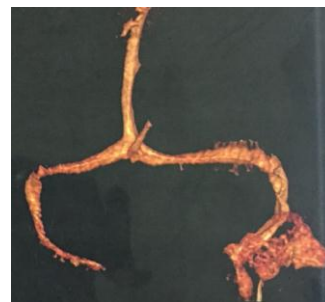
Temporal paragangliomas	No.	%
<i>Inferior tympanic branch of Asc. pharyngeal artery</i>	8	100%
<i>Neuromeningeal branch of Asc. pharyngeal artery</i>	8	100%
<i>Stylomastoid branch of occipital artery</i>	4	50%
<i>Caroticotympanic and cavernous branches of ICA</i>	2	25%
<i>Pial branches of ICA and VBS</i>	2	25%
Carotid body tumor		
<i>Musculospinal branch of ascending pharyngeal artery</i>	2	100%
<i>Ascending cervical artery</i>	1	50%
Vagal paragangliomas		
<i>Musculospinal branch of ascending pharyngeal artery</i>	1	100%
<i>Muscular branches of occipital artery</i>	1	100%



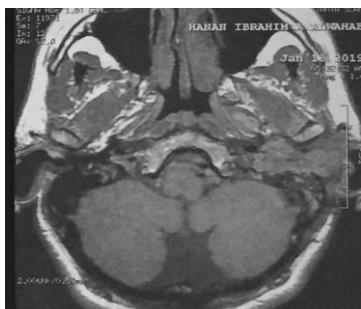Enhanced CT showed LT temporal enhanced tumor mass



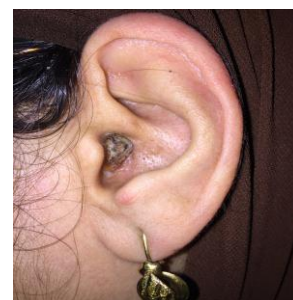
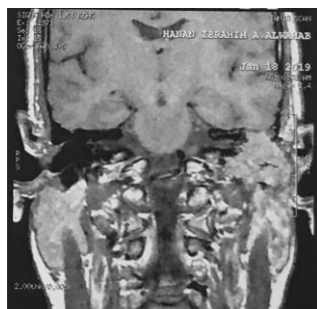Bone window showed temporal bone erosion



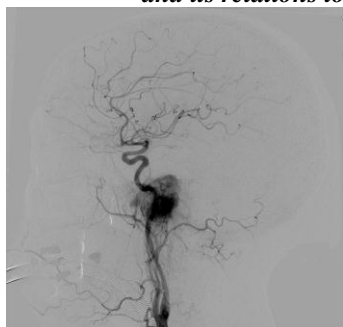CT Venography showed relation of tumor to sigmoid sinus



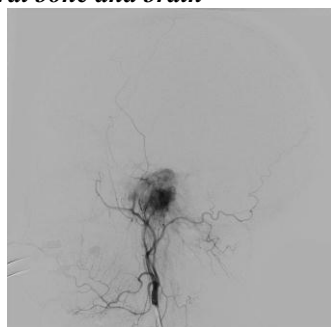
Enhanced MRI in axial and coronal views showed enhanced tumor mass and its relations to temporal bone and brain



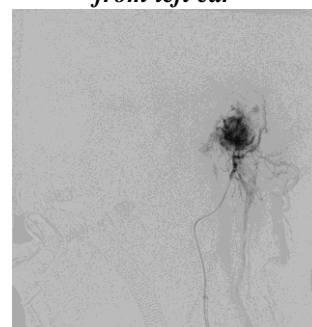
Pulsatile tumor mass protruding from left ear



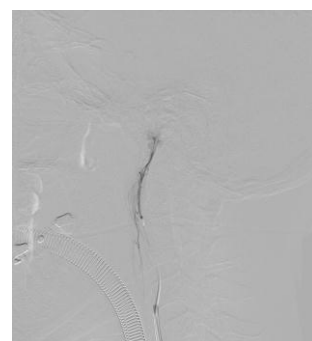
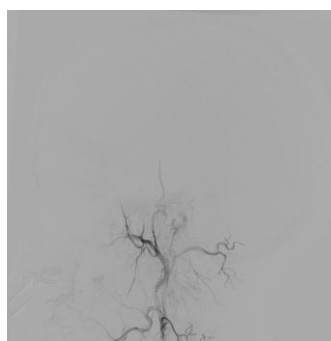
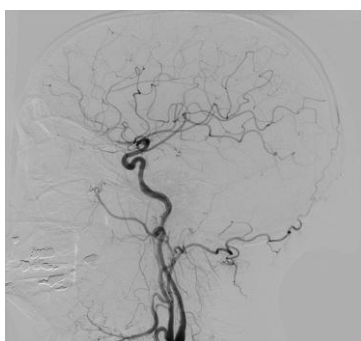LT CCA Lat showed tumor blush



Selective ECA Lat showed tumor blush

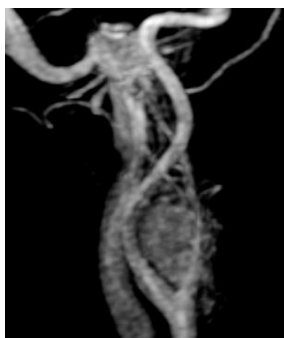


Superselective catheterization of Asc Ph A showed tumor blush

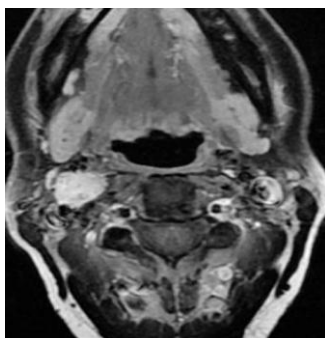


Control DSA from LT CCA, ECA, Asc Ph A showed total obliteration of tumor blush

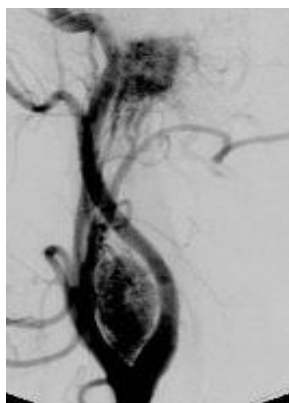
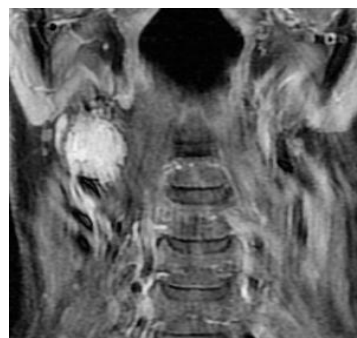Case (1) Female patient 45 years old had left temporal paraganglioma presented with pain, pulsatile tinnitus, left sided hearing loss and mass protruding from ear. CT bone window showed erosion of the temporal bone and enhanced CT and MRI showed tumor mass. Preoperative super-selective transarterial embolization was done with total obliteration of tumor blush.



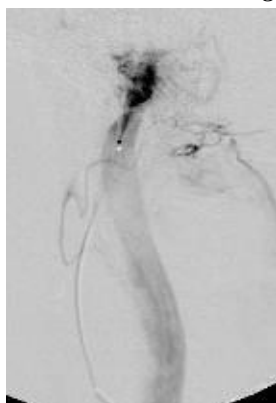MRA showed tumor blush



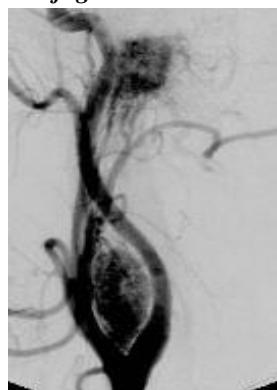
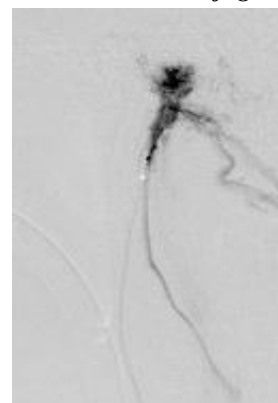
Enhanced MRI axial and sagittal views showed tumor mass in jugular fossa



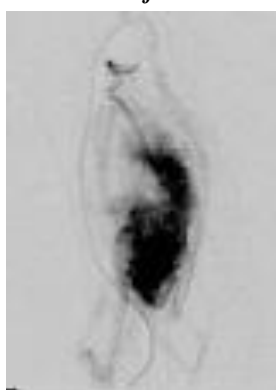RT CCA showed tumor blush in both location jugular and carotid body



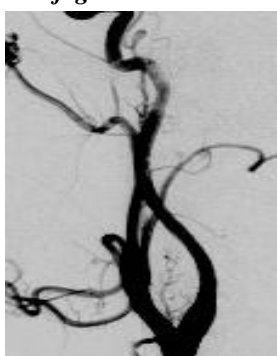
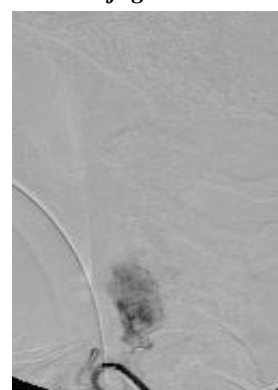
Super-selective injection from inferior tympanic and neuromeningeal branches of Asc Ph A showing tumor blush in jugular location



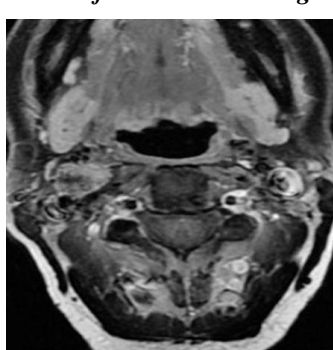
RT CCA showed tumor blush in both location jugular and carotid body



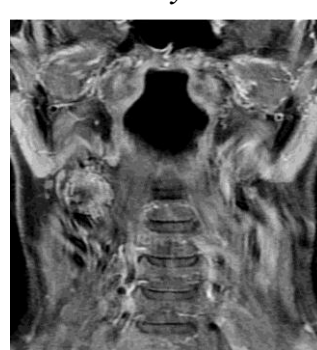
Super-selective injection from muculospinal branches of Asc Ph A showing tumor blush in carotid body location



Control DSA from RT CCA showing total obliteration of tumor blush in both locations



Post embolization enhanced MRI showing central necrosis of tumor mass in jugular fossa



Case (2) Female patient 48 years old with multifocal paraganglioma (jugular fossa and carotid body) presented with painful neck swelling and pulsatile tinnitus. Enhanced MRI showed tumor in both locations. Preoperative super-selective transarterial embolization was done with total obliteration of tumor blush in both locations.

Discussion

Most common locations for paragangliomas in our study included Temporal location (middle ear and jugular fossa) in 80%, carotid body location in 20% and vagal location in 10%. The incidence of paraganglioma subtypes in our series is close to that reported in the larger series of 224 head and neck paragangliomas by Papaspyrou et al. They had 53% temporal paragangliomas, 30% carotid body tumors and 12% glomus vagale tumors.[21]

In our study 1 patient have multifocal paraganglioma including temporal and carotid body locations. Multifocal head and neck paraganglioma have been reported in 10 - 20% of sporadic cases with higher incidence up to 80% in familial cases. [4]

Hormonal activity of head and neck paragangliomas is very rare (1%-3%). No one of our patients had clinical or biochemical evidence of hormonal activity of their paragangliomas. No history of hypertensive crisis or increased 24-hour urine catecholamine excretion. Papaspyrou et al. had only one of their 175 patients, with head and neck paragangliomas, who showed evidence of excess catecholamine excretion.[21, 22]

There is still much debate about the optimal treatment for head and neck paragangliomas. These lesions are almost benign with very slow rate of growth. It takes almost ten years for a paraganglioma to double in size. This natural history gives logic for watchful conservative treatment in the elderly. Radiotherapy allows good control of paraganglioma growth and offers the patient a worthy chance to preserve neurologic function and good quality of life for a long period of time especially for those with multiple lesions. Surgical resection is still the only option for complete reliable eradication of paraganglioma. Microsurgical techniques and preoperative embolization are important adjuvant to improve visualization, reduce operative blood loss and neurologic morbidity. [22-24]

Our embolization strategy is to perform superselective catheterization of the main feeding artery and to perform intra-tumoral embolization starting with small size particles (150-250) and gradually increasing the particle size. We aim, by embolization on tumor bed level, to control the blood flow from dangerous supplementary feeding arteries without catheterizing them. We always keep in mind the risk of paradoxical embolization of the brain or cranial nerves through potential anastomosis with internal carotid or vertebro-basilar arteries. So, we avoid the use of very small particle size (smaller than 100 micron), which can shunt through these dangerous anastomosis. We also perform frequent

intermediate angiographic control for early detection of opening of such anastomosis.

Post embolization enhanced images, intraoperative blood loss and histopathological examination of the resected specimen showed necrosis in most of cases with preoperative embolization that confirms the effects of preoperative embolization. Surgical reports, of our series, showed dramatic effect of preoperative embolization on limiting the amount of intraoperative blood loss and decreasing neurologic morbidity during surgical excision of paraganglioma. This goes with the results of White, et al. who had no evidence of neurological complications after preoperative embolization of 38 head and neck paragangliomas. They also reported decrease of intraoperative blood loss and neurological complications during surgical excision.[25]

No permanent morbidity or mortality related to endovascular embolization of paraganglioma in our series apart from one patient with silent small dissection in femoral artery and transient post embolization pain at the tumor site, which resolved within 48 hours with analgesics and steroids. Postembolization ear pain has been reported in other series and were related to tumor ischemia.[2, 12]

Conclusion

The outcome of patients in our study shows that preoperative embolization of head and neck paraganglioma is a very safe and effective adjuvant to surgical excision.

References

1. BOEDEKER, C.C., G.J. RIDDER, AND J. SCHIPPER, Paragangliomas of the head and neck: diagnosis and treatment. *Fam Cancer*, 2005. **4**(1): p. 55-9.
2. VALAVANIS, A., Preoperative embolization of the head and neck: indications, patient selection, goals, and precautions. *AJNR Am J Neuroradiol*, 1986. **7**(5): p. 943-52.
3. MILUNSKY, J.M., et al., Novel mutations and the emergence of a common mutation in the SDHD gene causing familial paraganglioma. *Am J Med Genet*, 2001. **100**(4): p. 311-4.
4. LEE, J.H., et al., National Cancer Data Base report on malignant paragangliomas of the head and neck. *Cancer*, 2002. **94**(3): p. 730-7.
5. DUNDEE, P., et al., Paraganglioma: the role of genetic counselling and radiological screening. *J Clin Neurosci*, 2005. **12**(4): p. 464-6.

6. FISCH, U., Infratemporal fossa approach for glomus tumors of the temporal bone. *Ann Otol Rhinol Laryngol*, 1982. **91**(5 Pt 1): p. 474-9.
7. SARINGER, W., et al., Paragangliomas of the temporal bone: results of different treatment modalities in 53 patients. *Acta Neurochir (Wien)*, 2002. **144**(12): p. 1255-64; discussion 1264.
8. VAN DEN BERG, R., Imaging and management of head and neck paragangliomas. *Eur Radiol*, 2005. **15**(7): p. 1310-8.
9. BERENSTEIN, A., et al., *Surgical Neuroangiography*. 2001, Springer.
10. KASPER, G.C., et al., A multidisciplinary approach to carotid paragangliomas. *Vasc Endovascular Surg*, 2006. **40**(6): p. 467-74.
11. TIKKAKOSKI, T., et al., Preoperative embolization in the management of neck paragangliomas. *Laryngoscope*, 1997. **107**(6): p. 821-6.
12. LASJAUNIAS, P., et al., Non chromaffin paragangliomas of the head and neck. Diagnostic and therapeutic angiography in 19 cases explored from 1977 to 1980. *J Neuroradiol*, 1981. **8**(4): p. 281-99.
13. FISCH, U., P. Fagan, and A. Valavanis, The infratemporal fossa approach for the lateral skull base. *Otolaryngol Clin North Am*, 1984. **17**(3): p. 513-52.
14. LASSEN-RAMSHAD, Y., et al., Paraganglioma of the head and neck region, treated with radiation therapy, a Rare Cancer Network study. *Head Neck*, 2019.
15. DUPIN, C., et al., Treatment of head and neck paragangliomas with external beam radiation therapy. *Int J Radiat Oncol Biol Phys*, 2014. **89**(2): p. 353-9.
16. TASAR, M. AND S. YETISER, Glomus tumors: therapeutic role of selective embolization. *J Craniofac Surg*, 2004. **15**(3): p. 497-505.
17. DUFFIS, E.J., et al., Head, neck, and brain tumor embolization guidelines. *J Neurointerv Surg*, 2012. **4**(4): p. 251-5.
18. PERSKY, M.S., et al., Combined endovascular and surgical treatment of head and neck paragangliomas--a team approach. *Head Neck*, 2002. **24**(5): p. 423-31.
19. MYSSIOREK, D., Head and neck paragangliomas: an overview. *Otolaryngol Clin North Am*, 2001. **34**(5): p. 829-36, v.
20. GUJRATHI, C.S. AND P.J. DONALD, Current trends in the diagnosis and management of head and neck paragangliomas. *Curr Opin Otolaryngol Head Neck Surg*, 2005. **13**(6): p. 339-42.
21. PAPASPYROU, K., et al., Head and neck paragangliomas: Report of 175 patients (1989-2010). *Head Neck*, 2012. **34**(5): p. 632-7.
22. PAPASPYROU, K., W.J. MANN, AND R.G. Amedee, Management of head and neck paragangliomas: review of 120 patients. *Head Neck*, 2009. **31**(3): p. 381-7.
23. GJURIC, M. AND M. GLEESON, Consensus statement and guidelines on the management of paragangliomas of the head and neck. *Skull Base*, 2009. **19**(1): p. 109-16.
24. HUY, P.T., et al., Evolving concepts in the management of jugular paraganglioma: a comparison of radiotherapy and surgery in 88 cases. *Skull Base*, 2009. **19**(1): p. 83-91.
25. WHITE, J.B., M.J. LINK, AND H.J. CLOFT, Endovascular embolization of paragangliomas: A safe adjuvant to treatment. *J Vasc Interv Neurol*, 2008. **1**(2): p. 37-41.

استخدام القسطره المخيه فى علاج الاورام الظهاريه

الخلفية: الاورام الظهاريه فى الرأس والرقبة عبارة عن أورام ذات تغذيه دمويه عاليه للغاية، وقد ارتبطت الجراحه لهذا النوع من الاورام بنسب مضاعفات عاليه للغاية. وقد وجد ان حقن هذه الاورام بطريقه انتقائيه فائقه عن طريق الشرايين بواسطه القسطره المخيه قد ادى الى تحسن النتائج الجراحيه.

الهدف: تهدف هذه الدراسه الى تقييمسلامة وكفاءة استخدام القسطره المخيه فى غلق التغذيه الدمويه قبل اجراء الجراحه للأورام الظهارية فى الرأس والرقبة.

الطرق: هذه الدراسه بأثر رجعي لجميع المرضى العشرة الذين يعانون من الأورام الظهاريه فى الرأس والرقبة الذين خضعوا للحقن قبل الجراحة فى قسم جراحة المخ والاعصاب بجامعة طنطا فى الفتره بين عامي ٢٠١٠ و ٢٠١٦.

النتائج: تضمن البحث عشرة مرضى يعانون من احد عشر ورم من الأورام الظهارية. ٨٠ ٪ من المرضى من الإناث. كان متوسط عمر المرضى ٤٧ سنة. جميع المرضى كانوا يعانون من الألم وطنين بالأذن عند التشخيص. تضمنت أنواع الأورام الظهارية الثانوية من ٨ اورام بالأذن و ٢ ورم بالجسم السباتى وورم واحد حول العصب الحائر. وكان متوسط غلق التغذيه الدمويه للورم نحو ٨٠ ٪.

الاستنتاجات: استخدام القسطره المخيه فى غلق التغذيه الدمويه قبل اجراء الجراحه للأورام الظهارية فى الرأس والرقبة هو وسيله مساعدة آمنة وفعالة للغاية فى الاستئصال الجراحي.